

A case of hyper-IgE syndrome

ACD de Alwis¹, Rajiva de Silva², Sepali Gunawardena², DC Weerasuriya³ and AHM Jayaweera³

(Index words: Recurrent bacterial infections, oral candidiasis, mycoses of nails, dentition abnormalities)

Summary

Hyper-IgE syndrome, a multi-system disorder affecting dentition, skeletal and immune systems and connective tissues, presents with recurrent infections and dermatitis. We report here the first case in Sri Lanka.

Case report

A 9-year old boy presented to General Hospital, Ratnapura, with fever, cough and haemoptysis of two

days' duration. Recurrent severe infections had been present from birth. Born to non-consanguineous parents, he developed recurrent skin abscesses and suppurating cervical lymphadenitis from the age of 3 days. These were drained 37 times and *Staphylococcus aureus* isolated. He developed bronchopneumonia at 5 and 8 months, and right lower lobe pneumonia with an encysted pleural effusion at 26 months. A pruritic dermatitis developed at 10 days of age, and onychomycosis with paronychia, and oral thrush were present from infancy. A BCG scar is absent.

¹Paediatrician, ³Registrars, General Hospital, Ratnapura, and ²Immunologist, Medical Research Institute, Colombo. Received 11 November 2005. Revised version received 4 May 2006, and accepted 10 May 2006. Correspondence: RdeS, e-mail: <nilhanrajivadesilva@yahoo.com>

On admission, he was febrile and in respiratory distress. He had a prominent forehead, deep-set eyes, broad nasal bridge, wide fleshy nasal tip and a prominent jaw (Figure 1). Oral candidiasis, mycosis of finger and toe nails, and infected pruritic eczema were noted. Over-retaining deciduous teeth and lingually erupting permanent teeth were present in two rows (Figure 2). He was tachypnoeic with diminished air entry, bronchial breathing and increased vocal resonance of right lower chest. Other systems were normal.

Investigations revealed a normal haemoglobin and platelet count, polymorphonuclear leucocytosis, raised ESR and C-reactive protein (CRP). Blood picture revealed toxic changes of neutrophils. Chest xray showed multiple, bilateral pneumatoceles and ultrasound scan of the abdomen showed a focal hypoechoic area of 20 cm³ in the right lobe of the liver, the aspirate from which contained neutrophils. Blood culture grew *Staphylococcus aureus*. Sputum was negative for acid fast bacilli.

Immunoglobulin IgG, IgA and IgM, Complement C3 levels, T and B lymphocyte and NK cell counts were normal. The T lymphocyte function, assayed by the proliferation of T cells to the mitogen concanavalin A, was normal. The IgE level was elevated (2000 IU/ml, 95% confidence limit 527 IU/ml). Seroconversion following polysaccharide typhoid Vi vaccination was absent. The child was treated with intravenous cefuroxime and cloxacillin for 14 days, and ciprofloxacin for 7 days. After complete recovery he was discharged on oral cloxacillin prophylaxis.

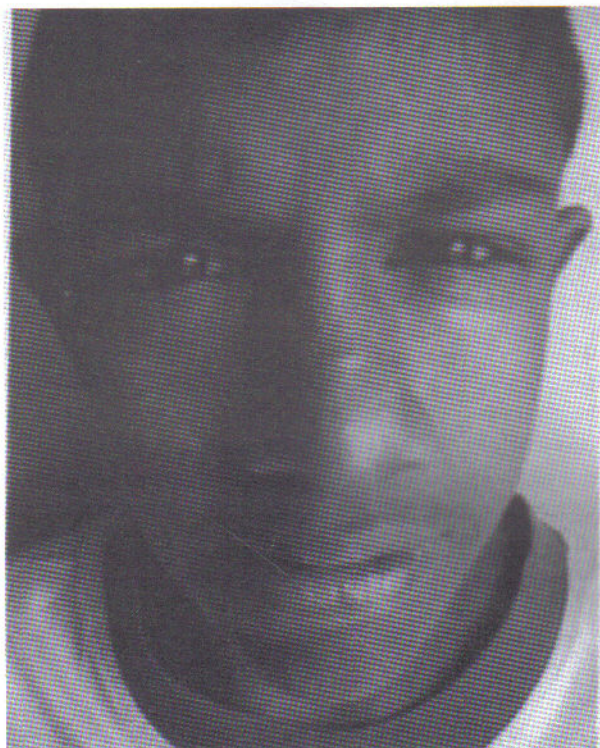


Figure 1. Facial appearance – note prominent forehead, and wide fleshy nasal tip.

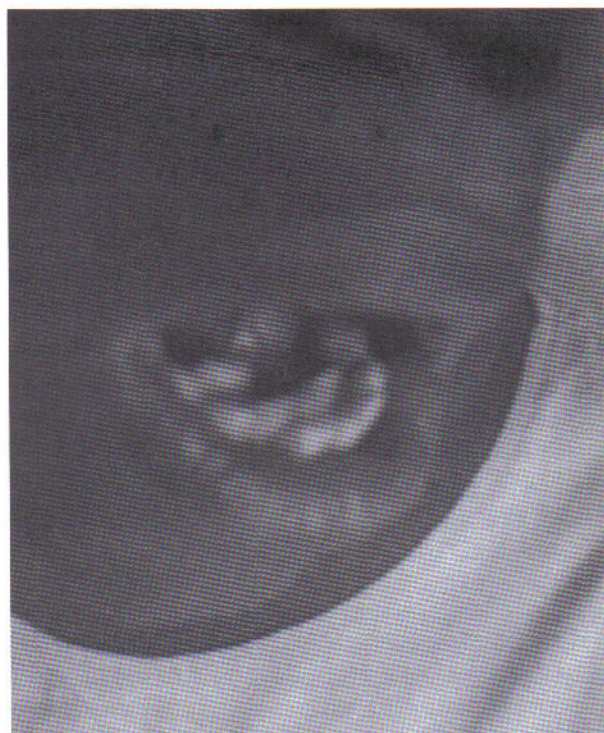

Figure 2. Two rows teeth due to delayed shedding of primary teeth.

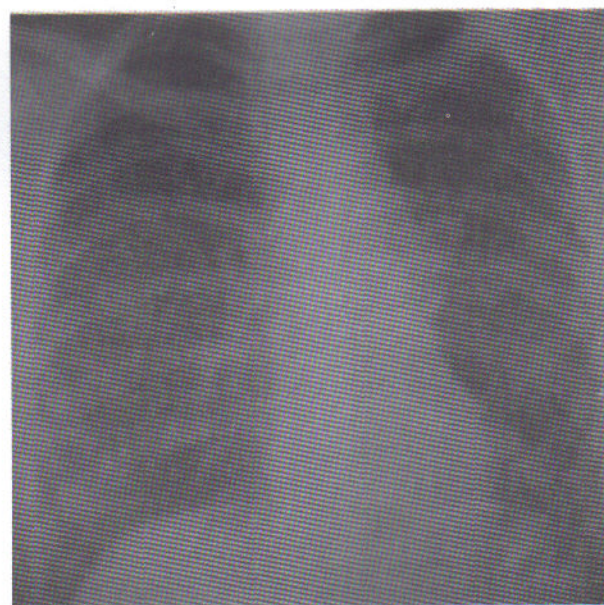


Figure 3. Miliary mottling due to possible infection with tuberculosis.

Four months later he presented with a 10-day history of low grade fever and cough. Chest xray revealed extensive miliary mottling (Figure 3). The ESR was 74mm and three consecutive samples of sputum for acid fast bacilli and serum for aspergillus antigen were negative. A presumptive diagnosis of miliary tuberculosis was made and he responded well to anti-tuberculous drugs.

Discussion

Described in 1973 [1], Job syndrome is probably the same condition [2]. It is a multi-system autosomal dominant disorder with variable expression, affecting dentition, skeletal system, connective tissue and the immune system [3]. Patients present with recurrent respiratory and skin infection, chronic eczema, extremely elevated IgE levels and eosinophilia [3, 4, 5]. Facial anomalies are seen in the majority of patients, along with fractures (57%) and scoliosis (76%), low bone densities, joint hyper-extensibility, and delayed eruption of secondary teeth [4]. Moderate to severe eczema, is almost invariably present, hours to weeks after birth [4].

Infections are common. Furunculosis due to *Staphylococcus*, and cold abscesses, pathognomonic of hyper-IgE syndrome are seen. Pneumonia, usually staphylococcal or due to *H influenzae*, end up with abscess formation and pneumatoceles. The resultant cavities are suitable environments for pseudomonal and aspergillus superinfection. Other than pneumonia, deep seated infections are uncommon [6]. However, this patient had a pyogenic liver abscess. Mucocutaneous candidiasis is seen in most patients. *Pneumocystis carinii* pneumonia, cryptococcal oesophageal infection and meningitis have been reported. Such infections are generally seen in patients with cell mediated immune defects. Mycobacterial infection with atypical presentations, and *Nocardia* infections have been noted [4]. The patient we report probably had pulmonary tuberculosis.

The T and B lymphocyte counts, gross T cell function and immunoglobulin levels are generally normal. However, antibody responses to protein and carbohydrate antigens are impaired. The patient did not respond to the polysaccharide typhoid Vi vaccine. Neutrophil chemotaxis is impaired in some patients. Ig E levels are typically over 2000IU/ml, as in this patient, but may fluctuate. He had no eosinophilia; in the study quoted [4], eosinophilia was noted in 93% of patients.

While the aetiology is not certain, an imbalance of TH1 and TH2 lymphocytes may be responsible for the defect [3]. Prophylactic antibiotics, skin care and prompt treatment of infection, and surgery for pneumatocele and lung abscess are required. Bone marrow transplantation provides the only cure. The patient we report is well at present and is being reviewed regularly in the paediatric clinic.

Acknowledgements

We thank the staff of the Department of Immunology, Medical Research Institute, and Paediatric Unit, General Hospital, Ratnapura, for their cooperation. We declare that we have no conflicts of interest.

References

1. Buckley RH, Wray BB, Belmaker EZ. Extreme hypergammaglobulinemia E and undue susceptibility to infection. *Pediatrics* 1972; **49**: 59-70.
2. Davis SD, Schaller J, Wedgewood RJ. Job's syndrome. Recurrent cold staphylococcal abscesses. *Lancet* 1966; **1**: 1013-5.
3. Grimbacher B, Holland SM, Gallin JI et al. Hyper-IgE syndrome with recurrent infections – an autosomal dominant multisystem disorder. *New England Journal Medicine* 1999; **340**: 692-702.
4. Uzel G, Holland SM. Phagocyte deficiencies. In: Rich R, Fleisher TA, Shearer WT, Kotzin BL, Schroeder HW. *Clinical Immunology – Principles and Practice*. 2nd ed. Mosby, 2001. Chapter 37, p 1-18.
5. Erlewyn-Lajeunesse MDS. Hyperimmunoglobulin – E syndrome and recurrent infections: a review of current opinion and treatment. *Paediatric Allergy and Immunology* 2000; **11**: 133-41.
6. Shemer A, Weiss G, Confino Y, Traw H. The hyper-IgE syndrome. Two cases and review of the literature. *International Journal of Dermatology* 2001; **40**: 622-8.